


Extensive Nonunion of the Amnion: An Unusual Presentation of Amniotic Band Syndrome?

Journal of Diagnostic Medical Sonography
XX(X) 1-3
© The Author(s) 2010
Reprints and permission: <http://www.sagepub.com/journalsPermissions.nav>
DOI: 10.1177/8756479310378891
<http://jdm.sagepub.com>


Donald Stephen Hill, AS, RDMS, APS, RT(R)¹

Abstract

Amniotic band syndrome is a relatively rare condition affecting approximately 1 in 1200 live births, where the amniotic membrane ruptures from the chorion, leaving the fetus exposed to injury due to entrapment of body parts within the membranous strands. This case demonstrates what appears to be virtually complete nonunion, or complete rupture of the amnion from the chorion with deformity and amputation of a fetal foot and toes revealed at birth.

Keywords

amnion, chorion, amniotic band syndrome

Amniotic band syndrome (ABS) is considered an accidental event and is believed to occur because of partial rupture of the amniotic sac early in embryologic development. The rupture involves only the amnion, but the chorion remains intact. Fibrous bands of the ruptured amnion float freely within the amniotic fluid and can encircle and trap fetal body parts.¹⁻³ Common abnormalities include cleft palate, cleft lip, and club feet,^{4,5} whereas severe cases can lead to decapitation and death.^{6,7} Upon review of past medical literature, no case studies demonstrating this degree of amniotic separation, nonunion, or rupture were found relating to ABS.

Case Report

A woman in her early 20s presented for an obstetrical sonographic examination for confirmation of dates. The examination was performed on a Toshiba Nemio system (Tustin, CA) using a 6.0-MHz phased-array transducer. The sonographic evaluation demonstrated a normal-appearing 13-week, 4-day single intrauterine pregnancy. Areas of nonfused amniotic membrane were observed anteriorly within the sac and considered normal at this stage in gestational development. The patient returned at 21 weeks for a routine anatomical survey. The fetus appeared structurally normal but was surrounded by loose, redundant, free-floating amniotic membrane (Figures 1-3). Upon further inspection, the membrane appeared completely free from the chorion except in the area of the umbilical cord insertion into the central placenta anteriorly. The membrane appeared to be contiguous and intact without evidence of

rupture, stranding, or fragmentation. With particular attention to the limbs, there did not appear to be any fetal entrapment at this time. Close follow-up was recommended because of the potential risk of entrapment sequence. Examination at another facility at 29 weeks confirmed extensive free-floating amniotic membrane but was inconclusive for any fetal entrapment. Fetal growth was appropriate for gestational age.

A male fetus weighing 5 lbs, 5 oz was delivered via cesarean-section at 37 weeks without difficulty. The fetus was surrounded by adhering amniotic membrane, sometimes referred to as delivery en caul.⁸ The infant's left foot was abnormal with the appearance of a club foot. The right foot was missing the second and third toes. The delivering obstetricians could find no evidence of entrapment of any body part by the amniotic membrane, specifically the feet. It is possible that the infant's feet may have become entangled within the redundant membrane, causing the feet abnormalities, and later became untangled. The infant appeared otherwise normal. The membranes and placenta were sent to pathology for further inspection. A normal-appearing 492-g placenta was observed with redundant membranes. The amnion appeared attached to the placenta at the base of the umbilical cord, with fluid accumulation

¹Narragansett Radiology, Narragansett, RI, USA

Corresponding Author:

Donald Stephen Hill, AS, RDMS, APS, RT(R), Narragansett Radiology, 360 Kingstown Road, Suite 105, Narragansett, RI 02882, USA
Email: dhill4324@aol.com

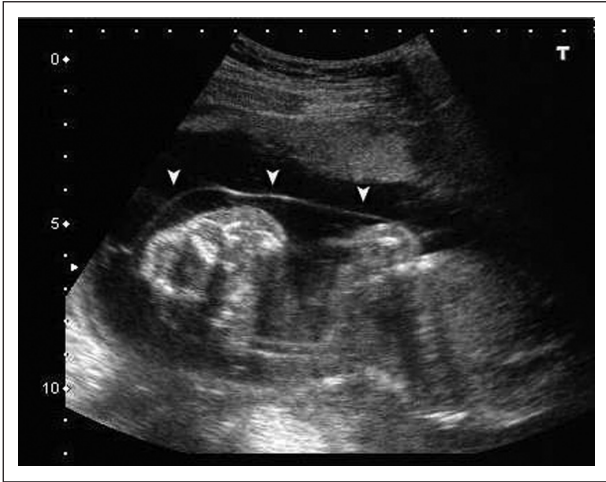


Figure 1. Amniotic membrane encircling the area of the fetal head and thorax.

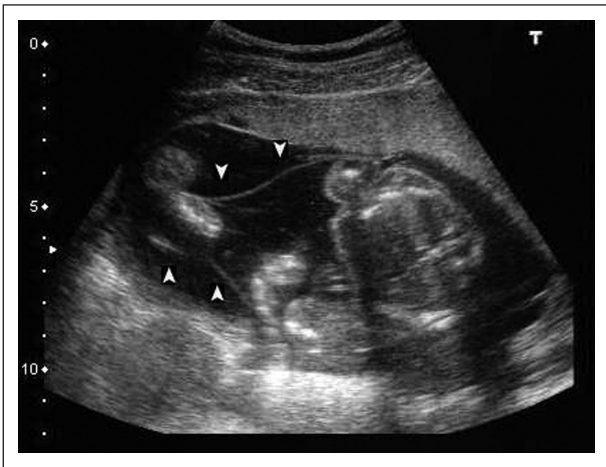


Figure 2. Amniotic membrane encircling the fetal thorax and limbs.

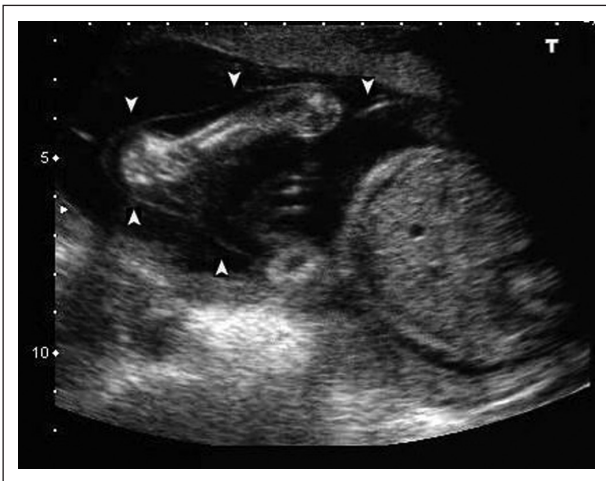


Figure 3. Amniotic membrane encircling the fetal arms and upper abdomen.

between the amnion and chorion. No areas of rupture, fragmentation, or stranding were observed. Microscopic evaluation demonstrated nonunion of the amnion from the chorion in most of the prepared microscopic sections.

Follow-up at 6 months postpartum revealed a healthy baby boy awaiting corrective surgery for the club foot abnormality involving his left foot.

Discussion

The chorion, amnion, allantois, and yolk sac make up the fetal membranes. The chorion originates from trophoblastic cells and remains in contact with the underlying uterine walls throughout the pregnancy. The amnion is ectoderm derived. It folds over the entire embryo as the cephalocaudal folding occurs, ultimately surrounding the entire embryo. As the embryo grows and folds ventrally, there is rapid expansion of the amniotic cavity with fusion of the amnion and chorion usually by 12 weeks, but it may be up to 16 weeks before it is finally completely fused.^{1,3,9}

ABS is considered an accidental event and does not appear to be genetic or hereditary. ABS is believed to occur because of partial rupture of the amniotic sac early in embryologic development. The rupture involves only the amnion, but the chorion remains intact. Fibrous bands of the ruptured amnion float freely within the amniotic fluid and can encircle and trap fetal body parts. As the bands constrict the growing fetus, growth abnormalities and amputations may occur.^{1,2,3,9} ABS may be the cause of 178 in 10,000 miscarriages.^{1,9} Up to 50% of cases have abnormalities, including cleft lip, cleft palate, and club foot deformities. Unilateral club foot can occur up to 30% of the time, whereas bilateral involvement occurs up to 20%.^{4,5,10} Hand, finger, and toe anomalies occur in up to 80% of cases.^{10,11} More severe cases can involve the abdomen (limb body wall complex)^{7,12} and calvarium (encephalocele).⁶ Prognosis and treatment depend on the location and severity of the constricting bands.^{1,3,9}

Conclusion

During the 21- and 29-week sonographic evaluations, the nonfused amniotic membrane appeared contiguous, without observable areas of rupture, stranding, or fragmentation. This was confirmed by the obstetrician's visual inspection of the membrane during delivery and further supported by gross and microscopic pathological evaluation. It is possible that the infant's feet may have become entangled within the redundant membrane, causing the feet abnormalities, and later became untangled, although this is conjecture. This case demonstrates a unique instance of virtually complete nonunion of the amnion rather than the classic segmental rupture associated with ABS. Upon review of past medical literature, no case studies demonstrating this degree of amniotic separation, nonunion, or rupture relating to ABS were found.

Declaration of Conflicting Interests

The author(s) declared no potential conflicts of interest with respect to the authorship and/or publication of this article.

Funding

The author(s) received no financial support for the research and/or authorship of this article.

References

1. Mahony BS, Nyberg DA, Pretorius DH, eds: *Diagnostic Ultrasound of Fetal Anomalies: Text and Atlas*. Chicago, Year Book, 1990.
2. Kawamura K, Chung KC: Constriction band syndrome. *Hand Clin* 2009;25:257–264.
3. Narang M, Khalil S, Faridi MM: Amniotic band syndrome. *J Pediatr* 2008;75:754.
4. Walter JH, Goss LR, Lazza AT: Amniotic band syndrome. *J Foot Ankle Surg* 1998;37:325–333.
5. Kincaid K, Rouse G, Wagner S: Prenatal sonographic detection of cleft lip and palate. *J Diagn Med Sonography* 1989;5:309–315.
6. Glass JM: Fetal decapitation associated with amniotic bands. *J Diagn Med Sonography* 2007;23:280–285.
7. Lurie S, Feinstein M, Mamet Y: Umbilical cord strangulation by an amniotic band resulting in a stillbirth. *J Obstet Gynaecol Res* 2008;34:255–257.
8. Abouzeid H, Thornton JG: Pre-term delivery by Caesarean section ‘en caul’: a case series. *Eur J Obstet Gynecol Reprod Biol* 1999;84:51–53.
9. Ross MG: Pathogenesis of amniotic band syndrome. *Am J Obstet Gynecol* 2007;197:219–220.
10. Allen LM, Silverman RK, Nosovitch JT, Lohnes TM, Williams KD: Constriction rings and congenital amputations of the fingers and toes in a mild case of amniotic band syndrome. *J Diagn Med Sonography* 2007;23:280–285.
11. Lohnes TM, Williams KD: Constriction rings and congenital amputations of the fingers and toes in a case of amniotic band syndrome. *J Diagn Med Sonography* 2007;23:383–384.
12. Goldfarb CA, Sathienkijkanchai A, Robin NH: Amniotic constriction band: a multidisciplinary assessment of etiology and clinical presentation. *J Bone Joint Surg Am* 2009;91(suppl 4):68–75.